

THERAPEUTIC HOTLINE

New insight in the treatment of refractory melasma: Laser Q-switched Nd: YAG non-ablative fractionated followed by intense pulsed light

PAULO ROWILSON CUNHA*, CLOVIS ANTONIO LOPES PINTO†, CAMILA BONATI MATTOS*, DAYANE PEVERARI CABRINI* & JOANA LUGLI TOLOSA‡

**Dermatology Department, Jundiaí Medical School, †Pathology Department, Jundiaí Medical School and ‡Jundiaí Medical School, Sao Paulo, Brazil*

ABSTRACT: The purpose of our study was to verify the results of the association of Q-switched Nd: YAG non-ablative fractionated with intense pulsed light, in order to treat patients with refractory melasma. The combination of these two devices seems to be the best treatment to combat hyperpigmentation produced by melasma, with low occurrence of side effects, which may be justified by the selective photothermolysis at subcellular level.

KEYWORDS: intense pulsed light, low-fluence laser, melanin pigment, melasma, ND:YAG laser

Introduction

Melasma is a common hyperpigmentation disorder that affects millions of people worldwide (1). The exact pathogenesis of melasma is unknown to date, but is believed to be associated with multifactorial etiology (1–7).

In general, pigmented lesions are characterized histologically depending on the part of the skin where the pigment lies, and can be grouped into three categories: lesions restricted to the epidermis, restricted to the dermis, or mixed lesions (reaching the epidermis and dermis; (4,8,9).

Address correspondence and reprint requests to: Paulo Rowilson Cunha, M.D, PhD, Rua Isai Leiner, 152 – Jardim Brasil – Jundiaí – SP – Brasil - CEP 13.201-854, or email: drpaulocunha@bol.com.br.

Although treatment of melasma can be done by topical formulations, chemical peels, and light source, in recent years, the laser has been used to treat various pigmented skin lesions, and the results have usually been successful (7,10,11).

Materials and methods

We have conducted an experimental study, approved and reviewed by the ethics committee of our institution (Jundiaí Medical School-Brazil). The experiment included 10 patients with clinical and histopathological diagnosis of refractory melasma, who attended at the Dermatology Ambulatory of the Jundiaí Medical School and particular outpatient clinic. All patients had tried topic treatment during 4 months with Kligman's

Table 1. Patient information and MASI calculation

Patient	Age (Years)	Time of onset of melasma	Skin phototype	MASI before laser	MASI after laser
A	33	≥ 1 year	III	4.9	3.7
B	37	≥ 5 years	III	6.3	5.7
C	37	≥ 1 year	IV	4.7	4.5
D	30	≥ 5 years	IV	8.7	5.94
E	39	≥ 10 years	III	7.8	5.7
F	37	≥ 5 years	IV	15.5	8.4

formula before being submitted to laser application. The study was conducted during the period from August 2012 to May 2013, aged from 20 to 60 years old. However, there has been withdrawal of patients during treatment, leaving only six to complete all applications at the end of the study. We used the platform Harmony^{xl} of Alma Lasers (Israel), with two different spots in the same session: handpiece AFT (Intense Pulsed Light) 540 nm with low fluence (12–14 J/cm²) and high pulse (12–15 ms) associated with Clearlift handpiece (Q-switched Nd: YAG non-ablative fractionated), spot size of 5 mm, 1064 nm, pulse width of 20 nanoseconds, fluence 800–1000mJ/P, pulse repetition rate 2 Hz. The patients underwent three laser sessions, respecting the 1-month interval between each new session. In each session, there was one application of intense pulsed light (IPL), whereas Q-Switched Nd:YAG had three different applications (horizontal, vertical, diagonal). Between the sessions, all patients used a topic formulation with Kligman's formula, ceasing the application during 10 days following each session.

The selected patients were clarified by researchers as to the purpose of the present study and the confidentiality of personal information, and later asked about their participation in this research. Before entering the study, all were advised to wear sunscreen of broad-spectrum daily and cease any other skin treatment.

After signing the free term of consent, the lesions were photographed with a digital camera (Nikon D90 AF-S micro Nikkor 105mm 1:2.8G), in three different positions: frontal, right, and left sides. Subsequently, the area severity index (MASI) was calculated.

All patients were submitted to biopsies, and the sections were stained with Hematoxylin-Eosin (HE), Fontana-Masson, and antibody Melan-A immunohistochemistry reactions.

After three laser sessions, all were once more photographed and the MASI was again calculated (1,12).

Results

The study initially included 10 patients. However, there was a lack of adherence and commitment to follow-up and patients failed to attend to laser sessions at the scheduled time. At the end of the study, we relied on the participation of only 6 patients with refractory melasma.

The members of the study had a mean age of 35.5 years and were classified according to Fitzpatrick skin type before the first laser session. Half had Fitzpatrick skin type III and the other half Fitzpatrick IV (Table 1).

Considering the results obtained in biopsies, all patients had mixed involvement of melanin pigment (dermal + epidermal). It was observed that all showed epidermal positivity with HE, Fontana-Masson, and Melan-A. Regarding dermal involvement, all were positive with Fontana-Masson staining, but two showed no Melan-A positivity and three showed no melanophages with HE staining (FIG. 1).

Considering the affected regions, the most frequent and most darkly pigmented was the malar region (90%), and of these, 90% had bilateral involvement. The area of lowest frequency of involvement was the chin region (66%).

In the present study, the MASI index was subjected to statistical analysis to assess the significance of the results obtained with the laser application and reduction of hyperpigmented lesions of refractory melasma. The previous score was 8.0 with a standard deviation of ± 4.0 , and the score after application of the laser was 5.7 with standard deviation of ± 1.6 . The difference between score before and after the laser is -2.3 with standard deviation of ± 2.5 .

According to the WILCOXON paired test, p equals 0.0313, proving that there is statistical significance in the reduction of hyperpigmented lesions of patients with refractory melasma using the association of Q-switched Nd: YAG non-ablative fractionated (QS) with IPL.

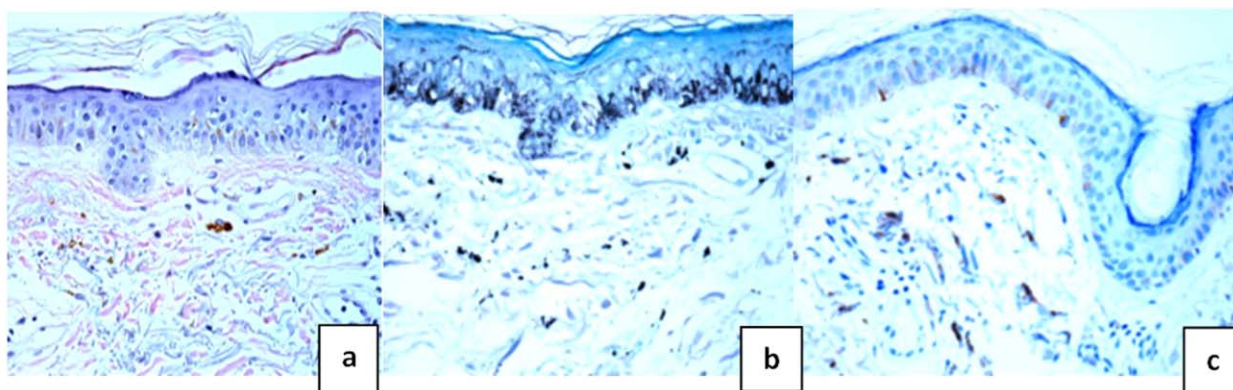


FIG. 1. Biopsies stained with HE, Fontana-Masson, and Melan-A. a: Histological section stained with hematoxylin-eosin at magnification of 400x demonstrates melanin pigment (brown) in keratinocytes and melanophages of the basal layer of the epidermis and in the superficial dermis. b: Histological section stained with Fontana-Masson in 400× magnification demonstrates melanin pigment stained in black in keratinocytes of the basal layer of the epidermis and in melanophages in the superficial dermis. c: Histological section of immunohistochemistry with Melan-A antibody (clone A-103, Ventana) at 400× magnification demonstrates melanin pigment (brown) in keratinocytes and melanocytes in the basal layer of the epidermis and melanophages in the superficial dermis.

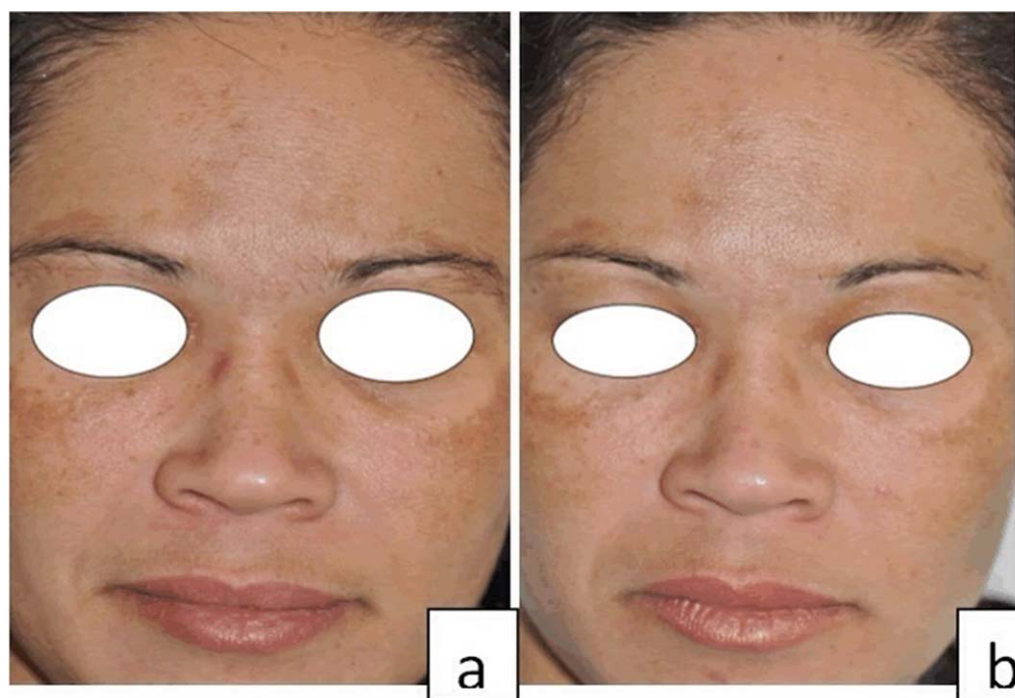


FIG. 2. Before and after laser application in patient Fitzpatrick IV. a: Before first laser application. b: 30 days after third laser application (IPL + Q-Switch Nd:YAG fractionated). Evident lightening of pigmented lesions, mainly in malar regions and forehead.

Regarding side effects, all patients experienced mild pain, redness, and peeling skin after applications. These changes had remission within 7 days.

Discussion

According to the literature and our findings, most cases of melasma have dermal and

epidermal (mixed) involvement, which justifies the use of lasers that can reach both superficial and deep layers of the skin, proving the association of IPL with Q- 1064 nm to be a valid method in cases of refractory melasma. It is important to consider new controlled, comparative and blind studies with long follow-up.

Throughout the study, gradual improvement has been observed in areas with hyperpigmentation, which were submitted to applications with the combination of IPL with QS 1064 nm. The Q-Switched Nd Yag non-ablative fractionated has an effective high potency pulse and the 1064nm helps to penetrate deep into the skin, removing dermal pigmentation and is preferred in elevated skin types. Besides, the very short duration of the pulse (20 nanoseconds) allows minimal thermal damage to adjacent tissues. It is noteworthy that QS applies the new concept of selective photothermolysis at the subcellular level, having minimal thermal damage and minor inflammation reaction to the tissue affected by pigmentation, which provides comfort to the patient without downtime (13,14).

The association of IPL + QS shows large action coverage against the melasma. This is due to the fact that AFT 540 nm captures melasma with epidermal involvement more effectively (thanks to its wavelength range, which is absorbed by melanin), while QS captures the pigment more thoroughly, fighting both the epidermal and dermal hyperpigmentation of the skin and blood vessels (7,11,15).

Although fractional ablative treatments (e.g., Er:YAG, CO2 Lasers) are growing alternatives for melasma treatment, the technique reaching melanosomes and melanocytes cannot be achieved with such lasers.

In our research, there were no references in literature about studies conducted in patients with refractory melasma submitted to treatment with laser-light association. The combined treatment has no down time as ablative lasers have, as well as low risk of rebound. Our study demonstrated improvement of the areas affected by pigmentation through the MASI index, photos (before and after; FIG. 2) and testimonies by the patients themselves, with few and reversible side effects.

Conclusion

Our study found that the combination of laser Q-Switched Nd Yag non-ablative fractionated +

IPL is an effective treatment for refractory melasma, having few side effects and good results, both objectively and subjectively, endorsed by the patients themselves.

REFERENCES

1. Sheth VM, Pandya AG. Melasma: A comprehensive update Part I. *J Am Acad Dermatol* 2011; **65**(4): 688–697.
2. Nouri K, Bowes L, Chartier T, Romagosa R, Spencer JM. Combination treatment of melasma with pulsed CO2 laser followed by Q-switched Alexandrite laser: a pilot study. *Dermatol Surg* 1999; **25**: 494–497.
3. Rokhsar CK, Fitzpatrick RE. The treatment of melasma with fractional photothermolysis: a pilot study. *Dermatol Surg* 2005; **31**: 1645–1650.
4. Li Y-H, Chen JZS, Wei H-C, et al. Efficacy and safety of intense pulsed light in treatment of melasma in Chinese patients. *Dermatol Surg* 2008; **34**: 693–701.
5. Ortonne JP, Arellano I, Berneburg M, et al. A global survey of the role of ultraviolet radiation and hormonal influences in the development of melasma. *J Eur Acad Dermatol Venereol* 2009; **23**: 1254–1262.
6. Nussbaum R, Benedetto AV. Cosmetic aspects of pregnancy. *Clin Dermatol* 2006; **24**(2): 133–141.
7. Ball Arefiev KL, Hantash BM. Advances in the treatment of Melasma: A review of the recent literature. *Dermatol Surg* 2012; **38**: 971–984.
8. Lee HI, Lim YY, Kim BJ, et al. Clinicopathologic efficacy of copper bromide plus/yellow laser (578 nm with 511 nm) for treatment of melasma in Asian patients. *Dermatol Surg* 2010; **36**: 885–893.
9. Taylor CR, Anderson RR. Ineffective treatment of refractory melasma and postinflammatory hyperpigmentation by Q-switched ruby laser. *J Dermatol Surg Oncol* 1994; **20**: 592–597.
10. Wang CC, Hui CY, Sue YM, Wong WR, Hong HS. Intense pulsed light for the treatment of refractory melasma in Asian persons. *Dermatol Surg* 2004; **30**: 1196–1200.
11. Wattanakrai P, Mornchan R, Eimpunth S. Low-fluence Q-switched neodymium-doped yttrium aluminum garnet (1,064 nm) laser for the treatment of facial melasma in Asians. *Dermatol Surg* 2010; **36**: 76–87.
12. Amit GP, Linda SH, Rafia B, et al. Reliability assessment and validation of the Melasma Area and Severity Index (MASI) and a new modified MASI scoring method. *J Am Acad Dermatol* 2011; **64**(1): 78–83.
13. Mokos ZB, Lipozenčić J, Čeović R, Buzina DS, Kostović K. Laser therapy of pigmented lesions: pro and contra. *Acta Dermatovenerol Croat* 2010; **18**(3): 185–189.
14. Anderson RR, Parrish JA. Selective photothermolysis. Precise microsurgery by selective absorption of pulsed radiation. *Science* 1983; **220**: 524–527.
15. Catorze G. Laser: fundamentos e indicações em dermatologia; *Med Cutan Iber Lat Am* 2009; **37**(1): 5–27.